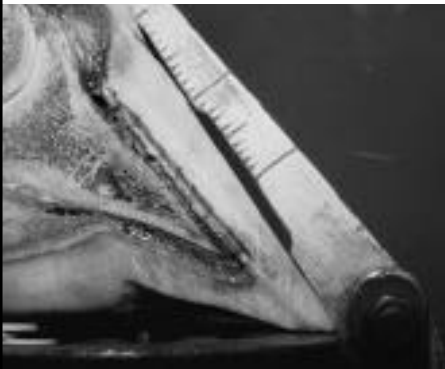
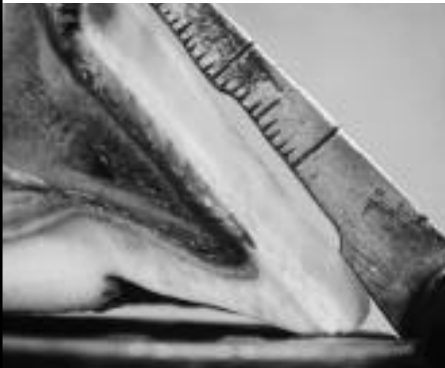

The Angular Dilemma:

Easily-manipulated angle readings are not proof
that the hoof has been functionally altered by wall dressing

By Rob Sigafoos



Changing the measured hoof angle without changing the angular position of P-3 requires only simple thinning with the rasp at the toe. On the foot at left, you can see the increase in the toe angle as measured on the gauge . . . but there is no effect on the angle of P-3. How many owners would know?

WE TRIM HORSES with the assumption that preferentially removing more hoof wall from the toe will have three therapeutic effects on the foot: 1) increase the measured hoof angle (when measured using a hoof gauge); 2) decrease the stress on the deep digital flexor tendon; and 3) increase the tendency for the horse's hoof to contact the ground heel first.

But how accurately can we measure the resulting new toe angle?

Even more importantly, is it possible to change the measured angle of the hoof without changing the position of P-3, changing the stress on P-3, or changing the way the hoof contacts the ground?

And, ultimately, is it possible to fraudulently demonstrate to an owner or trainer that the angle has been increased . . . without removing any length of toe at all?

The answer is that it is quite simple to change the measured hoof angle without affecting the other aspects of the hoof. One simply has to trim off the front of the hoof wall (see photo).

In extreme cases with unethical purposes, unscrupulous practitioners can manipulate laminitic hooves to disguise rotation on radiographs.

In these photos, one can see that thinning the lower section of the hoof wall at the toe will significantly change the measured hoof angle. However, the trimming did not affect the orientation of the coffin bone (P-3) to the ground.

It is important, therefore, to differentiate between the measured hoof angle and the angular position of the coffin bone when discussing hoof balance in the DP (longitudinal) plane.

Lowering heels or increasing toe angle alone will not necessarily re-orient P-3 to a ground level position. Angular position changes of P-3 can only be evaluated by before-and-after radiographs.

Rob Sigafoos is Chief of Farrier Services at the University of Pennsylvania School of Veterinary Medicine's New Bolton Center.